

# The Outdoorsman

Bulletin Number 37

January 2010

## Dr. Valerius Geist's Response to the Claims That Hydatid Disease Spread by Wolves Does Not Represent a Significant Threat to Humans

When the news broke that hydatid disease had established itself in the Northwest of the United States, I quickly responded, stating some of the precautions hunters should take in the field. As a Canadian field biologist I had been well instructed about hydatid disease in my training, which reinforced what I knew since childhood because a relative of mine died of hydatid disease.

During my career, friendships with medical people experienced with that disease reinforced what I knew. It's nothing to fool around with! Consequently I am a bit concerned about recent statements that take a rather cavalier attitude towards the disease.

The pro and contra machinations pertaining to wolves are of little concern here. What is important is that people living or recreating in areas with hydatid disease take precautions, while steps have to be undertaken to eradicate the disease.

To those supporting wolf conservation, let me make it clear: if wolves are going to survive in the Northwest, it will be wolves without infestations with dog tape worms. On this point, ludicrous as it may seem today to some, all parties can and should unite.

The more each party does its homework, the more likely this happy event will come to pass!

To reiterate briefly: because infected wolves, coyotes, dogs, foxes but also putty cats small and big, like mountain lions, or even raccoons, may carry dog tapeworm, or fox tapeworm or a number of related species of tapeworms, all of which are bad business, it is important that feces from carnivores is treated with great care – as well as the handling of carcasses and skins of carnivores **in affected areas.**

Because the tiny eggs, liberated by the millions in carnivore feces, are dispersed even by slight air currents, it is important for reasons of personal health not to poke or kick such feces. It will usually be dry and will then liberate clouds of tape worm eggs and this cloud of eggs will settle on your clothing, your exposed skin, in your sinuses and

windpipe, on your lips and if you inhale through the mouth in your oral cavity.

If you lick your lips, the eggs will get into your oral cavity. When sinuses and windpipe clear themselves of inhaled particles with your sputum, the eggs will get into your mouth and be swallowed with sputum. If you touch the feces or even poke it chances are the cloud of tiny eggs will also settle on your hands, and may contaminate the food you handle or eat.

People with dogs are at risk because their dogs may feed unbeknown to them on carcasses or gut piles of big game infected with that disease, infecting themselves with dog tape worm. These dogs will defecate in kennel and yards, spreading the tiny eggs. They will also lick their anus and fur spreading the eggs into their fur. The eggs will cling to boots and be carried indoors, where they float about till they settle down as dust. Now everybody is at risk of infection, especially toddlers crawling around on the floor. Putty cats can also be involved.

Hunters and ranching folks keeping or hunting with dogs in areas infected with hydatid disease are thus much more at risk than urban populations. The disease is silent, difficult to detect till very late, innocuous when the infection is light, provided the cyst is not interfering with vital functions, but lethal if it does, especially if cysts form in the brain. Fox tapeworm infections are worse. New is that some drugs help contain the disease but in many cases surgery is required. Unfortunately, the surgery can be very tricky.

To control the disease, we may have to do controlled burning of big game winter ranges to burn off the eggs. We should also consider targeting known wolf packs with medicated bait to purge them of tapeworms.

I wrote this much in an article in press and sent the manuscript to a colleague in Finland, Dr. Kaarlo Nygren, a game biologist working on hydatid disease, asking him if I was correct or if I had exaggerated in any way or form. The

*continued on page 2*

## Hydatid Disease – *continued from page 1*

following is his reply which confirms what I have written and also describes what happened when wolves infected with *E. granulosus* tapeworms were introduced into his area.

Valerius Geist, PhD. Professional Biologist  
Professor Emeritus of Environmental Science  
The University of Calgary

Dear Val,

I am indeed working on *Echinococcus granulosus* even after my retirement (on) 1/3/2010, because it appeared to be spreading in my own home area, Karelia, both sides of the Fenno-Russian border. I am afraid it will not only affect our staple food and essential part of our heritage, moose, but also us directly.

Hunters, dog owners, forest workers, berry and mushroom pickers will indeed be in danger. I agree in all you told in your paper; none of it is exaggeration.

So far, the largest hydatid disease outburst was in the sixties and seventies in northernmost Lapland where it severely affected reindeer-keeping people. It came with the wolves.

I still remember dramatic articles of that period describing aerial extermination offensives against the wolves; never before or after that have we used airplanes with soldiers using "Suomi" submachine guns against wildlife! Wolf population was thinned out by all means.

I also have, among memories from my younger days, a radio program where the local Game Chief (we have 15 such in Finland) gave instructions how to shoot a wolf through the window - what gun and cartridges one should use and how close to the glass one should keep the barrel when the beast is watching through it.

After this (extermination) operation, much work and propaganda was needed to clean the reindeer herding dogs in and out. But it was done. Now, this new wolf wave brought the parasite in again.

Beginning from the reindeer area, findings gradually spread southwards along the eastern border. Last spring, I was asked to (examine) a moose found dead in the snow near Värtsilä, where we have an important border and customs station with about a million passengers annually coming and going.

The moose was almost hairless (for a reason we were unable to confirm) but it had hydatid cysts in many organs, particularly lungs.

I sampled the contents by injection needle and in a droplet placed on an objective glass, thousands of things like miniature human skulls with sharp teeth (my first impression!) were seen. This was the first case of *E. granulosus* for me. I have seen thousands of *Taenia* cysts in our moose after opening thousands of carcasses but this was something else. And it was in *my* moose herd.

I quickly organized a sampling in that game management unit (in which) the moose was found and in the neighborhood also; hunters gave me a total sample from their bag for last year. We did lungs only and used official state vets to make it officially very clear.

It was shown that every 5th moose was carrying it in their lungs. Since liver seems to be among the very first organs normally affected, there may be an even higher prevalence than observed.

I told about our findings in a Swedish speaking radio program in Finland and it also was heard in Sweden. The chief of Swedish hunters association, Dr.vet.med. Torsten Mörner, commented and revealed that it has been found in Sweden also, after the re-appearance of wolves. Prof. Pjotr Danilov has started some kind of a program to find out the situation on his side of Karelia.

Last March, a large wolf was killed by hunters near the border on (the) Russian side. It had been seen on our side also several times and had caused fear only by its size. The weight measured soon after killing was 79 kilograms (174.2 pounds). We still seem to have some of that size alive.

It is no wonder why the Karelian Orthodox people living in villages feared wolves, killed them by all means but also considered dogs being not clean enough to be allowed inside human dwellings.

A dog in the village chapel, not to mention in monasteries, almost caused a burning and re-building of the house. At least thorough cleaning and religious rituals were needed.

One should also keep in mind, that in an orthodox home, a set of hand washing equipment near the door was as essential as icons on the opposite right-hand corner shelf. Before even greeting the people, the incoming person was supposed to wash his hands, dry them with a specially decorated towel, then make a cross sign with his right hand and bow towards the icon. Then, he was asked to step further.

Here, the homologies with other religious groups like Jews and Muslims automatically come to one's mind. Do not eat pork (trichinosis danger!), do not drink or eat blood or you might die in bacterial poisons! Wash your hands to avoid hydatid disease!

Our hunters are just starting to understand what this all means. So do our veterinarians. The first concern of the lady dissecting our moose lungs was: "How should we publicize this without the risk that people start demanding all our wolver be killed?"

Best wishes for 2010.

Kaarlo Nygrén  
Game and Fisheries Research Institute  
Ilomantsi Game Research Station  
Ilomantsi, Finland

# The Wildlife Disease Cover-Up That May Put You and Your Family at Risk

By George Dovel

When I was growing up, personal safety was pretty much a matter of using common sense and, if we were lucky, having a parent or others who were also older and more experienced teach us about life's hazards. Now we rely on government "experts" to protect our health and well-being – but what happens when the experts ignore our welfare to promote an alien agenda that can harm us?

In the Dec. 2009 *Outdoorsman*, I exposed the four year cover-up by Idaho Dept. of Fish and Game (IDFG) and Montana Fish, Wildlife and Parks (FWP) officials of the fact that wolves are spreading a new strain of hydatid disease in both states. I anticipated the usual damage control propaganda and it wasn't long in coming.

Two days after the internet version of that article was circulated in Montana, an article titled, "**Infestation in wolves poses no danger to humans, livestock, officials say**," appeared in the *Billings Gazette*. The article quoted three of the researchers who documented the existence of cystic hydatid disease in big game species in the two states and documented a massive infestation of the tapeworm that causes the disease in two-thirds of the wolf intestines they examined.

## "More Deer and Elk Infected Than People Realize"

FWP veterinarian Deborah McCauley said she doesn't believe the *Echinococcus* tapeworm will have any harmful effect on the Montana's elk herds and added, "In ungulates it doesn't cause a significant disease." In that Montana article, IDFG veterinarian Mark Drew refrained from commenting on the impact of the disease on elk and deer in Montana but said, "There are more deer and elk infected than people realize."

The study's lead author, veterinary parasitologist William Foreyt of Washington State University, admitted he believed the parasites were brought in by the wolves transplanted from Canada and expressed amazement at the degree of infection. "I was absolutely shocked to see such a high prevalence," he said. "Some of these wolves had tens of thousands of tapeworms. They were massively infected."

## Study Author Claims Humans Have to Eat the Eggs in the Feces to Become Infected

Although Foreyt admitted such high prevalence increases the possibility the tapeworm will spread, he said transmission of the tapeworm to humans or livestock is unlikely. "*For humans to contract the tapeworm, they would have to somehow come into oral contact with a wolf's feces,*" he said.

In an apparent reference to Dr. Geist's warning he said poking around in dried wolf feces might release the

eggs into the air, but said the person would have to ingest the eggs, not just inhale them, for the tapeworm to take root. "*You'd have to eat the eggs in the feces,*" he insisted

But that is not true. Keeping your mouth closed and breathing through your nose will not prevent you from swallowing the eggs if they are in the air. The "motile cilia" found in the lining of our windpipe and air passages constantly sweep mucous with trapped dust, parasite eggs, bacteria, etc. up out of the lungs to the back of the throat where it is swallowed. (Geist personal communication)

And their claim in this and subsequent newspaper accounts, that only those animals grazing in the vicinity of wolf feces will ingest the eggs is similarly misleading. As each pile of fresh wolf feces begins to dry, the eggs, like weed seeds, are released and transported by wind, water and assorted mammals, birds and especially insects over what is often a considerable distance from the original site.

## Foreyt – "It Really is Not Going to Affect People"

A similar article in Idaho's *Lewiston Tribune* nine days later mentioned my December 2009 article and Dr. Geist's warning. Although Foreyt did not repeat his earlier claim that in order for humans to get the disease they would have to have oral contact with wolf feces, he was quoted as follows:

*"The news media have overblown this - that it is going to affect people and animals and it really is not. If this wildlife strain ever does affect people, they usually don't produce any serious problems."*

To which IDFG veterinarian Drew added that *people diagnosed with the disease can be treated with medication.*

The first "expert" contradicted himself in the very next sentence and the second neglected to explain the circumstances when medication will help and, as is most often the case, when surgery is needed. Yet the reporter repeated the self-serving sound bites and ignored Dr. Geist's explanation of the *facts* he provided.

## Origin of the Claim That Sylvatic Disease is Mild

Claims that the northern wild animal (sylvatic) strain of cystic hydatid disease does not cause serious problems in humans can be traced to two events:

a) The cysts normally grow slowly inside your body for months, years, or in some cases even several decades without any symptoms to indicate their presence.

b) A review of 101 reported cases in Alaska by Wilson et al published in 1968, indicated that *some* pulmonary (lung) cysts may rupture "naturally," or are otherwise treatable with medication rather than surgery.

*continued on page 4*

## Disease Cover-Up – continued from page 3

More than 40 years ago when public health officials in Alaska were screening elderly Eskimos in an effort to detect tuberculosis in its early stages, chest X-rays revealed hydatid cysts in some of their lungs. None of these *pulmonary* cysts had produced *reported* symptoms, but several had ruptured with the infected person expectorating (hawking and spitting) the cyst contents.

Later, in 1973, Wilson reported that 30 of 36 lung cysts with no symptoms responded to medication without surgery and speculated that sylvatic cysts in the lungs may be less severe than those reported from “pastoral” strains (involving dogs and domestic sheep). The review suggested that most such cases in the lungs could be treated successfully with medication and that complications from the half of the cysts that ruptured were less severe in the long term than might have occurred with surgical removal.

At the time, it was assumed that most patients with hepatic or abdominal cysts were asymptomatic (without symptoms) and were never diagnosed. Educating Alaska residents to not feed uncooked meat or offal to their dogs, and the change from dog teams to snow machines by Eskimos probably contributed to the sharp decline in reported cases of human hydatid disease in Alaska.

### Two Out of Three Recent Cyst Infections Were Severe

From the mid 1950s through 1990, more than 300 cases of hydatid disease were reported in Alaska alone yet from 1990-1999 only three cases were reported. Two of those three cases occurred in 1999, with the first resulting in death and the second requiring a 30-day hospitalization involving delicate medical procedures to reduce the danger from surgery. It was followed by surgical removal and daily medication for 12 months following the surgery.

The first patient, a 51-year-old Caucasian woman, typically had no symptoms and the cyst was discovered by a physician during a physical examination. The lump detected on her abdomen was not tender and by using ultrasound, was diagnosed as a *simple* cyst on her liver.

A consulting surgeon and gastroenterologist agreed not to pursue further diagnostics or treatment due to lack of symptoms (pain, fever, etc.) and no evidence that it was a *hydatid* cyst. Three months later the woman began to experience pain and three days later she suddenly died.

### Cases Don't Fit Pattern Described by Biologists

The medical examiner determined the cause of death was probable anaphylactic reaction (shock) related to leakage of a hepatic *Echinococcus* cyst. Many daughter cysts, brood capsules and tapeworm larvae indicated a dangerous condition that is not supposed to happen in the sylvatic strain according to some wildlife biologists.

The second patient, a 17-year-old native woman from Southeast Alaska had two cysts on her liver when she entered the hospital after experiencing symptoms for eight days. Her 103-degree fever could not be lowered and she was transferred to a larger hospital for treatment.

The cysts were compressing the gall bladder and stomach and, as with the older woman, one cyst had leaked fluid. Neither victim fit the “classic” pattern of exposure to sled dogs but both lived not far from moose and wolf populations, and one had the neighbor’s dogs visiting her yard while the other had small dogs living in her house.

A discussion of these two cases by the eight specialists that were involved in every phase from treatment to confirming the sylvatic strain with genetic testing at an Australian facility, can be seen at: <http://www.ajtmh.org/cgi/reprint/66/3/325.pdf>. The paper emphasizes:

“Most reviews of ‘benign’ echinococcosis in Alaska were of pulmonary cysts discovered incidentally in older persons during TB screening programs. Because many of the earlier cases discovered incidentally were asymptomatic, a detection bias could have given the appearance that *Echinococcus* cysts grew quietly without consequences.”

### Studies Show Sylvatic Hydatid Disease Treatment Just as Complex as Dog-Sheep Version

In recent, far more representative medical reviews of hydatid disease patients conducted at teaching hospitals in Winnipeg and Edmonton, the number of *sylvatic* disease patients with liver cysts equaled or exceeded the number with lung cysts. Because these reviews did not include a non-representative sampling of elderly Eskimos with calcified lung cysts that were resolving (as the 42-year-old review had) the character of nearly all of the cysts in these studies could hardly be described as “benign.”

A paper, published in “The Canadian Journal of Infectious Diseases,” reviewed case histories of patients treated for the sylvatic strain of cystic hydatid disease at two hospitals in Winnipeg from Jan. 1987 through Dec. 1997. The review excluded patients who came from places where they might have been infected with the pastoral (domestic dog/sheep) strain and also excluded patients treated for the more deadly *E. multilocularis* tapeworm disease called “Alveolar Echinococcosis.”

Of the 17 sylvatic cases of hydatid disease treated, seven had lung cysts, seven had liver cysts, one had cysts in both lungs and liver and two had cysts in the spleen. Twelve were treated with surgery alone, two more with a combination of needle aspiration (suction) and surgery, and three received no curative treatment. One of the three had the cyst rupture later and was treated with medication and the other two did not return for follow-up examination.

An 18-year-old aboriginal woman had a cyst on her liver measuring 10-1/4 inches in diameter and was experiencing loss of appetite, severe pain, swelling and jaundice. Surgery could not be attempted until internal pressure from the cyst causing complications was relieved so a catheter was inserted through the skin and nearly four gallons of fluid was drained from the cyst over a two-week period. Then a combination of surgery and careful suction

of cyst contents was successful and the patient recovered following several months of daily medication.

The conclusion of this report published in the Canadian Journal of Infectious Diseases was: "Cystic hydatid disease is an uncommon infection in northern North America, but is similar in clinical manifestations to disease acquired in sheep-raising areas." The report also stated: "In the sylvatic variety, lung cysts may be more common. Most cysts are asymptomatic and are only discovered during investigations for other complaints. However, they may cause considerable pain, become infected and lead to anaphylactic shock, although rarely" (plus a list of other medical complications – see at: <http://www.ncbi.nlm.nih.gov/pmc/articles/PMC2094814> .)

A similar medical review of 42 patients hospitalized in Edmonton with echinococcal disease symptoms from 1991 to 2001, also included only known or suspected infections from the sylvatic strain of *E. granulosus*. Of 22 patients in which the specific disease was confirmed initially, 40% had lung cysts and 50% had liver cysts.

These patients ranged in age from 5-87 years and 32% had surgical removal combined with medical treatment, 27% had surgical removal alone, 18% had cyst aspiration, one had medical treatment alone and 18% received no corrective treatment.

Although the outcome of the patients was said to be generally good, significant pre-operative complications included two cyst ruptures infecting the bronchus, three infections of lung or liver cysts, and obstructive jaundice. Major complications after surgery included leakage of bile and of fluid from the lungs, wound infection, and abdominal bleeding requiring liver transplant.

The title of this review report was: "**Echinococcal disease in Alberta, Canada: more than a calcified\* opacity.**" (\*in a CT Scan the presence of a calcified cyst wall is suggestive of an inactive cyst such as those reported in some elderly Eskimos during the 1960s). In both this review and the review of sylvatic hydatid disease in the Winnipeg hospitals, significant complications often occurred despite the presence of calcification.

For example, five days after the birth of her baby a 28-year-old patient had pneumonia-like symptoms that did not respond to medication. Calcified hydatid cysts in the tongue cavity and one lung were discovered and surgically removed which resolved the problems.

Other case histories reveal that childbirth or a blow received during contact sports have ruptured a cyst which then necessitated surgical removal. Whether the cysts are sylvatic or pastoral in origin, calcified or actively growing, they can exist without symptoms in the human body for years and suddenly create a life-threatening circumstance.

The Calgary report, which can be seen at: <http://www.biomedcentral.com/1471-2334/5/34>, included the following statements in its summary:

"In comparing the clinical features and outcome of Canadian-born patients (presumed to have the sylvatic variant of *E. granulosus*) and foreign-born patients (who could have any type of *Echinococcus* infection), no differences were noted."

"A previous study from northern Canada and the United States described hepatic involvement in 71% of cases and pulmonary involvement in only 7% of cases. Previous reviews suggested that pulmonary cysts are more common in children and young adults while hepatic cysts are more common in older persons, which is compatible with our findings."

#### **Early Detection Essential to Prevent Complications**

Treatment at the Children's Hospital in Vancouver of three children aged 9-12 with single lung cysts reflects the conclusion that identification of hydatid cysts before they grow large enough to damage the organ is necessary to prevent complications. Two of the cysts responded to six months of treatment but the third fist-size cyst resulted in infection and surgical removal the damaged lobe after nine months.

Both of the reports emphasized the necessity to differentiate between a hydatid cyst on the liver and others such as simple cysts. Although this diagnosis may entail a degree of risk, they suggested pursuing it in areas where hydatid disease is known to exist.

They also pointed out that the number of cystic hydatid disease patients infected with the pastoral (domestic) strain of *E.* in Canada has decreased for several decades with recent increases in the number of patients infected with the sylvatic (wild animal) strain. But the authors in both studies felt the number of reported cases does not reflect the extent of infections in humans.

The Alberta study reported that efforts to worm concentrations of infected foxes with bait had been used to reduce infections, but said this was not considered practical in a vast country such as Canada. They reasoned that the extensive period between the time a human is infected and the point when the disease erupts with symptoms in some people prevents identification of the mode of infection.

"Conclusion: Until our understanding of the modes of transmission of ED improves, education of the public about this relatively rare disease is unlikely to be effective. Therefore, from a public health perspective, the emphasis must be on further progress in management of this disease, which will require increasing awareness on the part of physicians regarding the multitude of presentations, improved diagnostics, and further study of long-term outcomes with different treatment modalities."

(NOTE: A comparison of these statements from medical doctors whose agenda is to protect private citizens from disease, with the statements from wildlife officials whose agenda is to protect wolves and their parasites from private citizens, is revealing. – ED)

# IDFG “White Paper” Response to Concerns About Wolves Introducing New Strain of Hydatid Disease

By George Dovel

During the third week in January, I received a copy of the following well-circulated email from Idaho Dept. of Fish and Game Panhandle Region Supervisor Chip Corsi to the Panhandle Region employees he supervises:

“Some of you may have seen the latest from George Dovel’s “The Outdoorsman”. Based on Mark’s (IDFG veterinarian Mark Drew) assessments (attached), human health risk is quite low, provided you avoid consuming things like canid feces and uncooked organs; and I think suggests Dovel’s interpretation is more than a bit sensationalized. If you are handling wolves or coyotes, wear gloves. Risk to humans does not appear to be any greater than with other parasites found in wildlife that we, and hunters/trappers, routinely handle.”

At the risk of being accused of using this page for a personal rebuttal, I shall point out that here’s a biologist who drew \$84,000 in wages plus liberal benefits in FY 2009, yet who is willing to ignore biology in order to divert attention from the real issue. By concealing the fact that a *new strain* of *E. granulosus* tapeworm was contaminating tens of thousands of square miles of Idaho during the past four years, IDFG caused irreparable harm.

It put an unknown number of Idahoans at risk of being infected with a new strain of hydatid disease, including the Panhandle Region IDFG employees under Corsi’s supervision. The Department’s warning to wear gloves resulted from the truth finally being exposed, but it came four years too late. And Corsi’s inference that we must eat canine feces to become infected has generated emails from veterinarians in several states asking if Idaho biologists are really that dumb.

## IDFG Officials Ignore CDC Warning

The National Center for Disease Control (CDC) in Atlanta issued a fact sheet on *Aveolar Echinococcosis* (AE), the other variety of *Echinococcosis* disease that also exists in Montana, and is spread to humans by the *E. multilocularis* tapeworm which infects rodents and humans rather than big game and humans. The fact sheet, dated September 23, 2004, includes the following warnings applicable to both tapeworms whose eggs look exactly the same and are spread in exactly the same fashion:

- Don’t touch a fox, coyote, or other wild canine, dead or alive, unless you are wearing gloves.
- After handling pets, always wash your hands with soap and warm water.
- Do not collect or eat wild fruits or vegetables picked directly from the ground. All wild-picked foods should be washed carefully or cooked before eating.

“Because wild coyotes, foxes, and wolves are being trapped and transported to states where *E. multilocularis* has not previously been found, there is increased risk of spreading the disease to animals and humans.”

## IDFG “White Paper” Claims Potential for Human Exposure is “Relatively Low”

In the “White Paper” provided to the Idaho Legislature by IDFG Veterinarian Mark Drew and the Idaho Dept. of Agriculture, the view that Hydatid disease does not represent a serious threat to residents of Idaho and Montana mirrors the opinion expressed by Dr. Robert Rausch. In several published papers he considers the disease a threat only to indigenous (native) people who live with dogs in unsanitary conditions.

Rausch, a Professor Emeritus at the University of Washington, was the expert who identified the parasites in the study of Idaho and Montana wolf lower intestines conducted by Drew, Foreyt et al. He also participated in the review of 101 cases of cystic hydatid disease in Alaska published in 1968 by Wilson et al discussed in another article in this issue.

If you have already read that article, you will recall the authors in the Edmonton and Winnipeg reviews of medical case histories were critical of the 1968 study because the subjects had no symptoms and were not seeking medical treatment. Like them, most people infected with hydatid disease have the cysts growing inside them for 10-15 years before they either grow large enough to create problems or rupture.

During that extended period the cysts can be described as “benign” but eventually some of them will become painful and a few will cause sudden death. Unless an autopsy is performed the real cause of death may never be known.



On January 25, 2010 I emailed a copy of the “white paper” provided to the Legislature to Dr. Valerius Geist and asked for his comments. The following is his response which should be read carefully by everyone:

Dear Friends,

The important point about *Echinococcus granulosus* is not that it is a threat to hunters or biologists in the field, as spreading a bit of sensible know-how about proper sanitary measures will reduce chances of infections.

The problem with hydatid disease is that it is transmitted to dogs in rural areas, and that sanitary measures then are difficult to implement. When the

*continued on page 8*



**IDAHO FOR WILDLIFE**  
News Bulletin No.3

**MISSION STATEMENT**

“To protect Idaho’s hunting and fishing heritage. To fight against all legal and legislative attempts by some animal rights and anti-gun organizations that are attempting to take away our rights and freedoms under the constriction if the United States of America. To hold all Federal and State Agencies who are stewards of our wildlife accountable and ensure that true science is used as the primary role for our wildlife management.”

How would you like to be taking a quiet walk with your dog around your home place and find your dog rolling in wolf or dog scat, feces or what ever you want to call it? At that point you and your dog could be contaminated with *E. granulosus* eggs. (Tapeworms for short). This is how wolves and this parasite are coming to our local communities. Read below!!!!!!!!!!!!

COEUR d’ALENE, IDAHO—Tom and KJ Torgerson have seen all kinds of wildlife outside their Fernan Hill home, but they have never encountered wolf tracks, until now. The tracks were found in the snow outside their home, near the garage, patio and front door. PRIEST LAKE, IDAHO—Man shot wolf that was patrolling the neighbor hood where kids were at play. BOVILLE, IDAHO—A wolf has been seen around town, school, City Park. IDFG has been called, wolf still there. SUN VALLEY, IDAHO—Wolves around town chasing elk, been in peoples yard. **WOLVES WATCHING KIDS AT THE SCHOOL BUS STOP IN KAMIAH IDAHO. THE LIST JUST GOES ON AND ON.** This entire happening around where people and pets recreate. 90% of the wolves tested in these areas have tapeworms that can be passed to all livestock, pets’ wildlife and humans.

Your Idaho Fish and Game and the IDFG Commissioners received this report of the tapeworm infestation in 2006 and failed to inform the public of the danger about you hiking or hunting in your favorite wooded area.

We have another friendly parasite that wolves carry and are known to be here in the Northwest. Wolves are infecting livestock and wildlife in Minnesota. I am sure it is here; we just haven’t seen it yet as there have been no studies done by our State Agencies. The name of this little jewel is (*Neospora caninum*). Google it up and see what you find.

Another fine disease that wolves and dogs spread, along with coyotes, fox, skunks, kitty cats, big and small. The name is Cutaneous anthrax. This form of anthrax enters your body through a cut or other sores on your skin. It’s by far the most common form of the disease. It’s also the mildest—with appropriate treatment, cutaneous anthras is seldom fatal. Symptoms of the disease include. A RAISED, ITCHY BUMP RESEMBLING AN INSECT BITE THAT QUICKLEY DEVELOPS INTO A PAINLESS SORE WITH A BLACK CENTER. ALSO SWELLING IN THE SORE AND NEARBY LYMPH GLANDS. IT IS POSSIBLE THAT THIS HAS HAPPENED IN IDAHO.

**CHAPTERS ALREADY FORMED.**

BURLEY, MINI CASA CHAPTER. CONTACT GEORGE WARREL 208-312-0369, BILL STABLEY 208-431-0823  
SNAKE RIVER CHAPTER. BRYAN SPRAGUE 208-317-5785, MIKE OTTESON 208-233-6700  
WOOD RIVER CHAPTER, DALETHORNOK 208-847-5136  
BONNERS FARRY CHAPTER, KEVIN KEMP 406-363-5741

**NEW CHAPTERS FORMING.**

MOSCOW IDAHO, FEB. 15<sup>TH</sup> TIA AND ADAM STAGG 208-885-4213 OR 208-875-1347  
COEUR d’ALENE BOB BALSER 208-687-9262

SALMON RIVER, BELVIEW, LEWISTON, GRANGEVILLE, OROFINO COMING SOON.  
IF YOU ARE INTERESTED IN JOINING A CHAPTER OR FORMING ONE GIVE ME JIM HAGEDORN A CALL 208-883-3423 OR ANY OF THE ABOVE MEMBERS.

**LIKE UNCLE SAM, WE NEED YOU. JOIN NOW.**

JIM HAGEDORN, IDAHO FOR WILDLIFE 208-883-3423

Idaho's Official Response – *continued from page 6*  
infection of elk and deer with hydatid cysts exceeds half the population, then ranch dogs are at risk picking up the disease as the chances are high that they will feed when not supervised on dead deer and elk or on offal left by hunters.

Unbeknown to their owners the infected dogs begin to fill the yard with tapeworm eggs in an ongoing fashion. Even if the dog is not allowed into the house, people walking through the yard will carry the eggs into the house with dirt on their boots.

In any such house raising children, toddlers will be crawling on the floor and they will gather dust and dirt on their hands and put their hands in their mouth. Therefore wherever you have deer or elk around farms, ranches and hamlets, and wherever in such abodes there are dogs roaming about, there is a high probability that tapeworm eggs will be brought into homes continually. It is also hard to imagine such dogs not getting petted.

Since hydatid disease is a silent disease that takes time to develop, there is not likely to be a problem till a number of people down the road are affected seriously. Once detected, even the sylvatic form of *E. granulosus* is likely to lead to surgery – no insignificant medical intervention even if quite successful.

Some cases will be fatal because cysts do implant in the brain, even if most implant in the lungs and liver. We need to get on with deciphering how this disease can be eradicated in our game herds.

In Finland it was achieved, till colonizing wolves brought it once more from Russia. Since the much worse *E. multilocularis* is spreading in the NW and resides in coyotes, coyote hunters need to be informed to take sensible precautions.

Cheers, Val Geist

Our cost for printing and mailing is about \$25 per year.  
Please Clip Donation Coupon Below

Mail to: **The Outdoorsman**  
**P.O. Box 155**  
**Horseshoe Bend, ID 83629**

Name \_\_\_\_\_

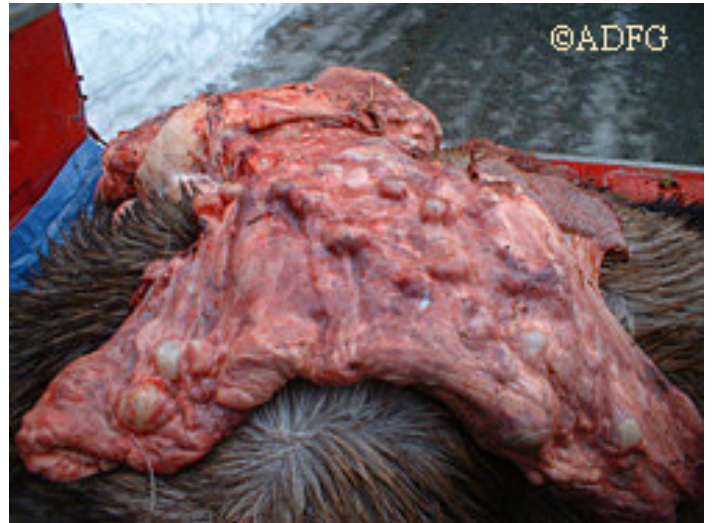Mailing Address \_\_\_\_\_

City \_\_\_\_\_ State \_\_\_\_\_ Zip \_\_\_\_\_

Amount Enclosed \_\_\_\_\_ Phone \_\_\_\_\_  
(optional)

New \_\_\_\_\_ Renewal \_\_\_\_\_ Extension \_\_\_\_\_ Gift \_\_\_\_\_

The claim by Montana FWP Veterinarian Deborah McCauley that she doesn't believe the *Echinococcus* tapeworm will have any harmful effect on the Montana's elk herds, ignores numerous research in other states, provinces and countries indicating that the increase in parasite infestation inevitably results in predators killing far more of the prey species.



Saskatchewan Research by Joly and Messier found when hydatid cyst infestation increased in moose lungs, wolves killed far more moose. (Photo courtesy Alaska Dept. of Fish and Game)

Based solely on the *opinion* of the Ag author of the "White Paper," Idaho Sen. Tim Corder sent the following email message: "*The increase of the wolf population does not constitute a threat to human health or domestic livestock.*" Yet a 4-fold increase in the fox population in Switzerland from 1980-1995 resulted in an emerging epidemic of deadly alveolar hydatid disease in humans.

Idaho citizens expect their elected officials to stop repeating the unsupported opinions from bureaucrats and make sound decisions based on documented facts.

PRSR STD  
US Postage Paid  
Horseshoe Bend, ID  
83629  
NO. 3